



## The Effect of *Hippophae rhamnoides* Extract on Oxidative Damage on Rat's Gastric Tissue Depending on Co-Implementation of Methotrexate and Indomethacin

Ismayil YILMAZ<sup>1</sup>, Ismail DEMIRYILMAZ<sup>2</sup>, Ebru SENER<sup>3</sup>,  
Nihal CETIN<sup>4</sup>, Yilmaz UCUNCU<sup>5</sup>, Durdu ALTUNER<sup>4</sup>, Nezahat KURT<sup>6</sup>,  
Semih C. KUNAK<sup>7</sup>, Abdullah KISA OGLU<sup>8</sup>, Bünyami OZOGUL<sup>8</sup> & Halis SULEYMAN<sup>\*4</sup>

<sup>1</sup> Department of General Surgery, Faculty of Medicine, Erzincan University, Erzincan, Turkey.

<sup>2</sup> Department of General Surgery, Ibni Sina Hospital, Kayseri, Turkey.

<sup>3</sup> Department of Pathology, Erzurum Region Education and Research Hospital, Erzurum, Turkey.

<sup>4</sup> Department of Pharmacology, <sup>5</sup> Department of Anatomy, Faculty of Medicine,  
Recep Tayyip Erdogan University, Rize, Turkey.

<sup>6</sup> Department of Biochemistry, <sup>8</sup> Departments of General Surgery,  
Faculty of Medicine, Ataturk University, Erzurum, Turkey.

<sup>7</sup> Department of Pharmacology, Faculty of Medicine, Ordu University, Ordu, Turkey.

**SUMMARY.** The effect of *Hippophae rhamnoides* (HR) extract on oxidative damage on rat's gastric tissue depending on co-implementation of methotrexate (MTX) and indomethacin (IND) was investigated biochemically and histopathologically. HR extract was given to HR extract-given (HRIM) group of rats with dose of 50 mg/kg, and to IND+MTX-implemented rat group (IMG) orally with distilled water through catheter. One hour after, IND and MTX combination was given to HRIM and IMG groups orally for 7 days with dose of 5 mg/kg. In gastric tissues of IMG group, the MDA amount increased to healthy-sham (SG) and HRIM groups. The amount of tGSH, in IMG group's gastric tissue decreased to SG and HRIM groups. Serious focal erosions, sub-mucosal edemas and mixed-type inflammatory cell infiltrations have been observed on surface epithelium of histopathological sections of stomachs of IMG group. HR extract prevent the gastric damage in rats' gastric tissues, which was formed by MTX and IND combination.

**RESUMEN.** El efecto del extracto de *Hippophae rhamnoides* (HR) en el daño oxidativo en el tejido gástrico de rata en función de la co-administración de metotrexato (MTX) e indometacina (IND) se investigó bioquímica e histopatológicamente. El extracto de HR fue dado a un grupo de ratas (HRIM) en dosis de 50 mg/kg y al grupo de ratas IND + MTX (IMG) por vía oral con agua destilada a través de un catéter. Una hora después, IND y la combinación de MTX fue dada a grupos HRIM e IMG por vía oral durante 7 días con dosis de 5 mg/kg. En los tejidos gástricos del grupo IMG, la cantidad de MDA aumentó en los grupos supuestamente sanos (SG) y HRIM. La cantidad de tGSH en el tejido gástrico de grupo IMG disminuyó a los valores hallados en SG y HRIM. Erosiones focales graves, edema sub-mucosa e infiltraciones de células inflamatorias de tipo mixto se observaron en la superficie del epitelio de las secciones histopatológicas de estómagos de ratas del grupo IMG. El extracto de HR previene el daño gástrico en tejidos gástricos de ratas, formado por la combinación de IND y MTX.

### INTRODUCTION

Methotrexate folic acid anti-metabolite is an anti-cancer medication. Besides the cancer diseases, it was used in the treatment of rheumatoid arthritis and many inflammatory diseases. Methotrexate (MTX) having a wide usage field may lead to gastrointestinal (GI) mucosal damage<sup>1-3</sup>. There may be GI system adverse effects due to implementation of MTX, such as stomatitis, mucositis, vomiting, and diarrhea. The GI system toxicity observed during MTX implemen-

tation is one of the leading reasons limiting MTX implementation. It was reported that the cells being sensitive to MTX at most are the fast-splitting cells such as GI canal mucosa<sup>4</sup>. Also it's reported that MTX increases malondialdehyde (MDA), one of the end products of lipid peroxidation, reduces the amount of glutathione (GSH) which is an endogenous antioxidant, and increases the 8-OH/Gua level which is the product of DNA damage<sup>5</sup>. In recent studies, it

**KEY WORDS:** Gastric tissue, *Hippophae rhamnoides*, Indomethacin, Methotrexate, Rat.

\* Author to whom correspondence should be addressed. E-mail: halis.suleyman@gmail.com

was reported that MTX creates severe oxidative damages on gastric tissues. Being MDA one of the last outputs of lipid peroxidation, it was found to be lower and the amount of glutathione (GSH), being an endogenous antioxidant, was found to be higher in the kidney<sup>6</sup> and ovarian tissues with oxidative injury<sup>7,8</sup>. Also MTX increases the MDA, decreases the amount of GSH and leads to increase in amount of 8-OH/Gua being a DNA damage output<sup>5</sup>.

In suppressing of pain, inflammation, and fever which were observed in many arthritis and inflammatory diseases, indomethacin (IND) and other non-steroidal anti-inflammatory medications are used with MTX<sup>9</sup>. But IND leads to serious damages and dangerous hemorrhages in GI system<sup>10</sup>. So, that may lead MTX-IND combination to create more serious GI adverse effects and to cause the stop of medication usage<sup>11</sup>. It is known that IND creates a gastrototoxic effect by increasing the hydrochloric acid secretion and suppressing the cytoprotective prostaglandin synthesis, mucus production, and bicarbonate secretion in gastric tissue. Also it was reported that IND leads to oxidative gastric damage by causing decrease in antioxidant amount in gastric tissue and increase in oxidant level<sup>12</sup>. It was experimentally shown that IND, depending on dose, suppresses GSH amount in gastric tissue, increases MDA amount, and leads to oxidative damage in DNA<sup>13</sup>. In prevention of GI damage due to co-implementation of IND and MTX, literature indicates the importance of powerful anti-oxidant treatment. The *Hippophae rhamnoides* extract (HR) which we used in this study was obtained from fruits of *Hippophae rhamnoides* L. (Elaeagnaceae)<sup>14</sup>. This herb contains carotenoids ( $\alpha$ ,  $\beta$ , and  $\gamma$ ), riboflavin, vitamin C, tocoferol, tocotrienol, folic acid and tannins<sup>15,16</sup>. The antioxidant, anti-ulcerogenic, radio-protective, anti-toxic, anti-coagulant, and anti-microbial effects of HR were shown<sup>17,18</sup>. HR extract was used in different ulcer models and found to be effective. But no literature information has been found about the effects of HR on oxidative gastric damage due to co-implementation of MTX and IND. In the light of this findings the aim of our study is to research the effects of HR on oxidative gastric damage due to co-implementation of MTX and IND biochemically and histopathologically.

## MATERIAL AND METHODS

### Animals

Twenty four albino Wistar rats were used in the study. The rats were obtained from Medical

Experimental Application and Research Center of Ataturk University, and their weights were varying between 230 and 245 g. Before the experiment, the animals were kept and fed in groups and under normal room temperature (22 °C). This study which were supplied from the Ataturk University Medical Experimental Research and Application Center. The protocols and procedures were approved by the local Animal Experimentation Ethics Committee.

### Chemical agents

The chemical materials used in experiment were provided by as follows: thiopental sodium from Ibrahim Ethem Ulagay-Turkey, methotrexate from Med-Ilac-Turkey, and *Hippophae rhamnoides* extract from Karen Bilim-Turkey.

### Rats Groups

Experimental animals were divided into 3 groups such as Healthy- Sham (SG), HR extract + IND + MTX given (HRIM) and IND + MTX given (IMG) rat groups. HR extract was given to HRIM rat group ( $n = 10$ ) with dose of 50 mg/kg, and to IMG group orally through a catheter. It's known that to cause gastric damage at such dosages of IND and MTX<sup>5,19</sup>. One hour after HR extract and distilled water implementation, both IND and MTX was given to HRIM and IMG groups with dose of 5 mg/kg. This procedure was repeated for 7 days. At the end of this period, all the animals were incised under high dose of anesthesia. Their stomachs were removed, and then investigated biochemically and histopathologically. The biochemical and histopathological results from HRIM group were evaluated by comparing with results of SG and IMG groups.

In order to test the acute toxicity, HR was administered by oral catheter to three different groups of rats ( $n = 6$  for each group) at 250, 500, 1000, and 2000 mg/kg doses and the survival of the animals was followed for 24 h. Toxicity was evaluated according to the animals died during the following period.

### Biochemical Analyses

#### Preparation of Samples

In this part of study, 0.2 g from each of stomach was weighed. Stomachs were homogenized in icy media containing 1.15% potassium chloride solution for MDA determination and 7.5 pH for GSH measurements by covering to 2 mL. Then they were centrifuged for 15 min at 4 °C and 10000 rpm speed. The supernatant part was used as analysis sample.

### Total Glutathione (tGSH) Determination

DTNB [5,5'-dithiobis (2-nitrobenzoic acid)] located for tGSH determination is a disulfide chromogen, and it is easily degraded by compounds with sulfhydryl groups. The formed yellow color is measured spectrophotometrically at 412 nm<sup>20</sup>.

### Determination of Malondialdehyde (MDA) Formation

This process is based on spectrophotometric measurement of absorbance of pink colored complex, which is formed by thiobarbituric acid (TBA) and MDA at high temperature (95 °C) at 532 nm wavelength<sup>21</sup>.

### Measurement of 8-hydroxy-2 deoxyguanine (8-OH Gua)

The amount of 8-OH Gua and guanine (Gua) were measured by using a HPLC system equipped with an electrochemical detector (HP Agilent 1100 module series, E.C.D. HP 1049 A), according to previously used protocols in our department<sup>22</sup>. The amounts of 8-OH Gua and Gua were analyzed on a 250 x 4.6 mm Supelco LC-18-S reverse-phase column. The mobile phase was 50 mM potassium phosphate, pH 5.5, with acetonitrile, and the flow rate was 1.0 mL/min. The detector potential was set at 0.80 V to measure the oxidized base. Gua and 8-OH Gua (25 pmol) were used as standards.

### Histopathological Analysis

The gastric tissues removed from rats were fixed in 10% formalin solution for 24 h. After routine tissue evaluation, 4 micron-thickness sections were taken from obtained paraffin blocks, and stained with haematoxylin & eosin (H&E). All the sections were evaluated under light microscope (Olympus BX 52, Tokyo, Japan) by a pathologist who didn't know which protocol was implemented.

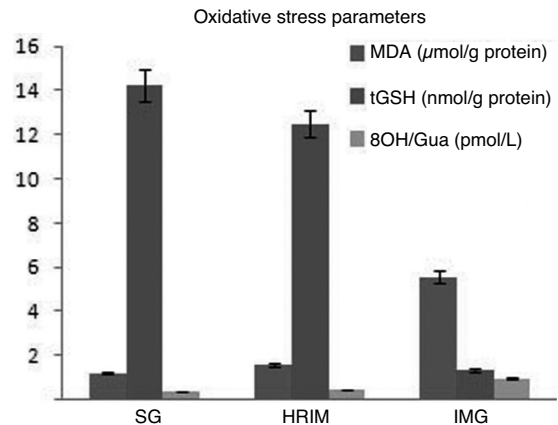
### Statistical Analysis

The experiment results were expressed as "mean  $\pm$  standard error of the mean" ( $X \pm SEM$ ). The significance of the difference between the groups was determined using the one-way ANOVA test. The Fisher's post-hoc Scheffe test was performed afterwards. All of the statistical processes were carried out using the "Statistical Package for Social Sciences 18.0 (Armonk, NY, USA) software" and p value of < 0.0001 was accepted as significant.

## RESULTS

### Biochemical results

As seen in Fig. 1, the MDA amount showed a



**Figure 1.** MDA, tGSH and 8-OH/Gua levels of the study groups in the rat gastric tissue. Results are expressed as the mean  $\pm$  standard error of the mean (SEM).  $P < 0.0001$ . All groups were compared with the IMG control group. Each group consisted of eight rats.

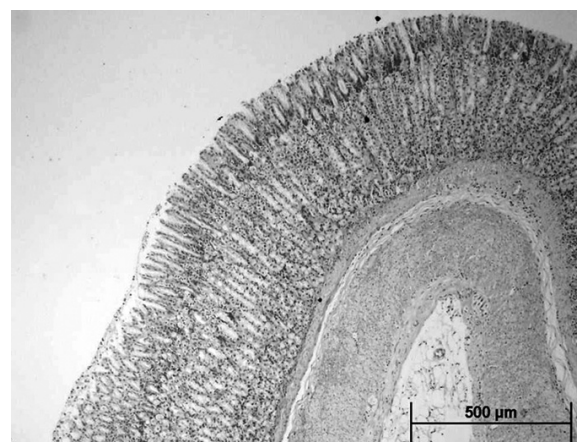
significantly increase in gastric tissue of IND + MTX given rat group (IMG) in proportion to healthy (SG) and HR extract given group (HRIM). But the amount of tGSH, an antioxidant parameter, showed decrease in gastric tissues of IMG group rats statistically significantly in proportion to SG and HRIM groups

### Acute Toxicity Findings

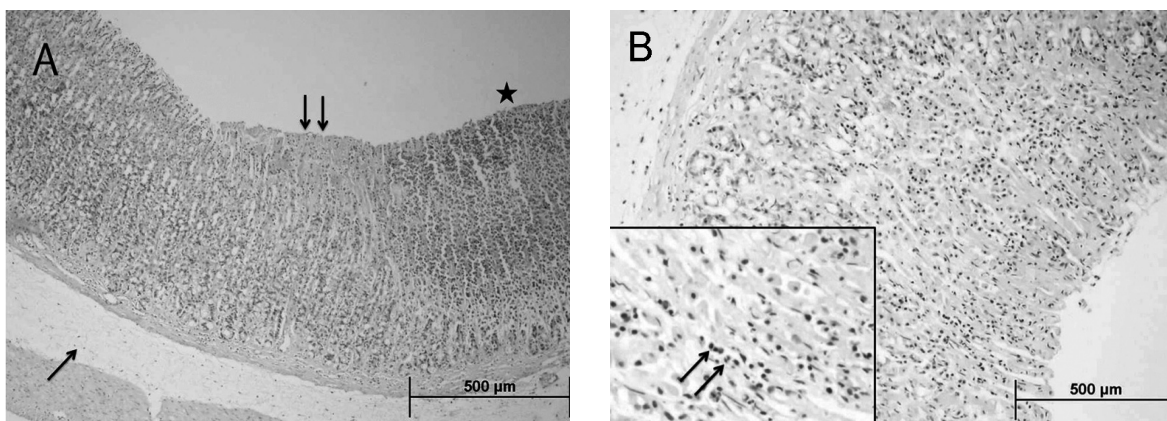
None of the animals died, given at a dosage range Orally 250-2000 mg/kg HR extract. Due to excess volume to be given in larger doses it has been impossible.

### Histopathological Results

Normal-appearing gastric mucosa and glands are observed in histopathological sections of stomachs of rats in SG group (Fig. 2). But in the

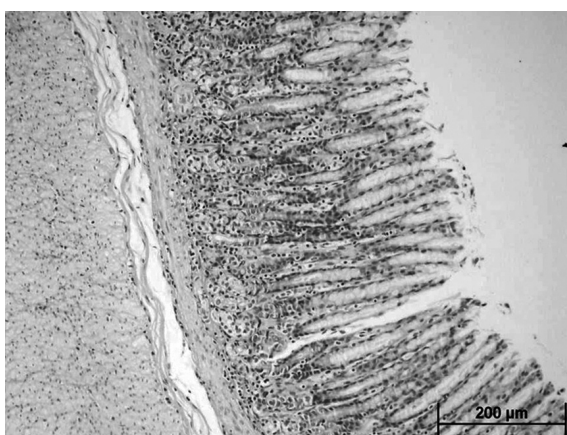


**Figure 2.** The histopathological examination of the gastric tissue of SG rat group (H&E, x4).



**Figure 3.** A) histopathological examination of the gastric tissue of IMG rat group (H&E, x4); B): histopathological examination of the gastric tissue of IMG rat group (larger image H&E, x10; small image H&E, x40).

neighborhood normal gastric mucosa (Fig. 3A, asterisk) serious focal erosions (Fig. 3A, double arrow) and sub-mucosal edemas (Fig. 3A, single arrow) are seen in histopathological sections of IND+MTX given IMG group rats. In the same area larger magnification the mixed type inflammatory cell infiltration (Fig. 3B, double arrow) in mucosa is noteworthy. It was determined that the mucosa has been protected in gastric tissues of HRIM rat group which HR extracts were given (Fig. 4).



**Figure 4.** Histopathological examination of the gastric tissue of HRIM rat group (H&E, x10).

## DISCUSSION

In this research, the effects of HR extract on oxidative gastric damage due to co-implementation of MTX and IND were investigated biochemically and histopathologically. Also acute toxicity of HR was investigated in rats. When enough healing cannot be obtained in arthritis and poly-arthritis treatments through IND and

other non-steroidal medications, MTX is added into treatment<sup>9,23</sup>. That leads to more severe oxidative stress in stomach<sup>11</sup>. While some of MTX-related adverse effects are related with folate antagonism, its adverse effects on tissues with high cell cycle, such as GI system, are related with toxic effect on gastric mucosa<sup>24</sup>. It was shown that the gastric damage creator effects of IND and other non-steroidal anti-inflammatory medications are related with local toxic effect on gastric mucosa<sup>25</sup>. In recent studies it was reported that MTX increased the oxidant parameters in gastric tissue such as MDA and MPO and also decreased the amount of GSH, an endogenous antioxidant<sup>5</sup>. It was suggested that taurine protects against methotrexate-induced oxidant organ injury and inhibits leukocyte apoptosis<sup>26</sup>. Also it was reported that IND increased the oxidant parameters in gastric tissues and decreased antioxidant parameters<sup>12</sup>. Demiryilmaz *et al.* showed that MTX increased the MDA amount in rat liver and decreased the amount of GSH<sup>27</sup>. Within our study, the MDA amounts in MTX+IND given rat group's gastric tissues were found to be significantly much higher, and the amount of GSH was found to be low. The difference between MDA and GSH amounts in gastric tissues of HR extract implemented and healthy rat groups was found to be statistically insignificant. That indicates that HR extract prevents the change of oxidant/antioxidant balance in gastric tissue in favor of oxidants. As it is known, under physiological conditions the oxidant/antioxidant balance is sustained with superiority of antioxidants<sup>28</sup>. The breach of this balance leads to tissue damages. This situation is named "oxidative stress"<sup>29</sup>. So, the existence of tissue damage is determined according to oxi-

dant/antioxidant balance<sup>30</sup>. While decreasing the gastric tGSH level by giving GSH antagonist diethyl maleate to experimental animals led to damage in gastric tissues, the reduced glutathione implementation prevented the gastric damage<sup>31</sup>.

GSH levels in gastric tissue of IMG group, one of the endogenous antioxidant defense mechanisms, were significantly decreased. Reduction of antioxidants and excessive increase of free radicals create DNA damage in not only lipids, but DNA molecules. 8-OHGua, has been recognized as an important parameter, indicating DNA oxidation<sup>32,33</sup>. 8-OHGua levels in gastric tissues of IMG groups rat found higher than SG and HRIM groups. There are several studies showing that increased the level of 8-OHGua, experimentally generated oxidative stress in different tissues<sup>22,34</sup>. Our experimental results are consistent with this literature.

The biochemical results of our study matches up with histopathological results. So, while serious focal erosion and edema and mixed-type inflammatory cell infiltration are observed in epithelium cells of gastric mucosa of IMG group where MDA level is high and GSH level is low, no pathological finding was reported in gastric tissues of HRIM and SG groups. Mucosal edema, erosion and inflammatory cell accumulation are important histopathological findings of gastrotoxicity<sup>35,36</sup>. It was shown that the lipid peroxidation leading to MDA increase and GSH decrease leads to disruption of unity of superficial epithelium cell membrane and damages on mucosa<sup>37</sup>. Also it was reported that the infiltration of inflammatory cells into gastric mucosa is one of the important mechanisms of gastric damages. Santucci *et al.* determined that TNF- $\alpha$  levels increased in parallel with neutrophil margination and mucosa damage in gastric damage cases<sup>38</sup>. The roles of activation of inflammatory cell (leucocytes) in free radical production are known. Researches showed the important roles of neutrophils in gastric pathogenesis; also the relationship between damages on superficial cells in stomach and superoxide anions and cations produced by leucocytes was reported<sup>39</sup>. There are studies showing that antioxidant medications inhibiting lipid peroxidation and inflammatory cell accumulation prevent the experimental gastric damage<sup>40</sup>. The prevention of oxidative gastric damage by combination of HR extract and MTX and IND is compatible with literature<sup>41,42</sup>.

## CONCLUSIONS

In conclusion, MTX and IND combination led to oxidative damage in gastric tissues of rats. It was biochemically and histopathologically shown that HR extract prevented the gastric damage raising due to MTX-IND combination in gastric tissues of rats. This characteristic of HR extract indicates that it will be useful in prevention of gastric toxicity developing due to combined long-term usage of MTX and IND. Also, the naturalness of HR extract may lead HR to be preferred in this indication rather than synthetic antioxidants.

## REFERENCES

- Loehry, C.A. & B. Creamer (1969) *Gut* **10**: 112-6.
- Nagakubo, J., T. Tomimatsu, M. Kitajima, H. Takayama, N. Aimi & T. Horie (2001) *Life Sci.* **69**: 739-747.
- Trier, J. S. (1962) *Gastroenterology* **42**: 295-305.
- Jolivet, J., K.H. Cowan, G.A. Curt, N.J. Clendeninn & B.A. Chabner (1983) *New. Engl. J. Med.* **309**: 1094-104.
- Demiryilmaz, I., H. Uzkeser, N. Cetin, A. Hacimuftuoglu, E. Bakan & D. Altuner (2013) *Asian J. Chem.* **25**: 2047-50.
- Yilmaz I., I. Demiryilmaz, M.I. Turan, B. Suleyman, I.S. Turan, D. Altuner, *et al.* (2013) *Lat. Am. J. Pharm.* **32**: 1231-5.
- Yilmaz, M., U. Isaoglu, N. Cetin, M. I. Turan, B. Suleyman, F. Gocer, *et al.* (2012) *Lat. Am. J. Pharm.* **31**: 1032-7.
- Isaoglu, U., M. Yilmaz, E. Sener, N. Cetin, D. Altuner, H. Bilen, *et al.* (2012) *Lat. Am. J. Pharm.* **31**: 1481-8.
- Cassidy, J.T. & R.E. Petty (2001) *Textbook of Pediatric Rheumatology*, WB Saunders Company.
- Giannini, E.H. & G.D. Cawkwell (1995) *Pediatric Clin. N. Am.* **42**: 1099-125.
- van Ede, A.E., R.F.J. M. Laan, M J. Rood, T.W. J. Huizinga, M.A.F.J. van de Laar, C.J. van Denderen, *et al.* (2001) *Arthritis Rheum.* **44**: 1515-24.
- Suleyman, H., A. Albayrak, M. Bilici, E. Cadirci & Z. Halici (2010) *Inflammation* **33**: 224-34.
- Polat, B., H. Suleyman & H. H. Alp (2010) *Chem.-Biol. Interact.* **186**: 82-9.
- A. Rousi (1971) *The genus Hippophue L. A taxonomic study*, Ann. Bot. Fennici.
- Suleyman, H., L.O. Demirezer, M. Buyukokuroglu, M.F. Akcay, A. Gepdiremen, Z.N. Banoglu, *et al.* (2001) *Phytother. Res.* **15**: 625-7.
- Andersson, S.C., K. Rumpunen, E. Johansson & M. E. Olsson (2008) *J Agr Food Chem.* **56**: 6701-6.

17. Guliyev, V. B., M. Gul & A. Yildirim (2004) *J. Chromatogr. B* **812**: 291-307.
18. Suleyman, H., K. Gumustekin, S. Taysi, S. Kelles, N. Oztasan, O. Aktas, *et al.* (2002) *Biol. Pharm. Bull.* **25**: 1133-6.
19. Brzozowski, T., P.C. Konturek, R. Pajdo, S.N. Kwiecien, S. Konturek, A. Targosz, *et al.* (2005) *Inflammopharmacology* **13**: 317-30.
20. Sedlak, J. & R.H. Lindsay (1968) *Anal. Biochem.* **25**: 192-205.
21. Ohkawa, H., N. Ohishi & K. Yagi (1979) *Anal. Biochem.* **95**: 351-8.
22. Malkoc, I., N. Cetin, D. Altuner, A. Hacimuf-tuoglu, N. Gursan, E. Bakan, *et al.* (2012) *Lat. Am. J. Pharm.* **31**: 537-44.
23. Prieur, A.M. & M. Dougados (1998) *Baillieres Clin. Rheumatol.* **12**: 181-374.
24. van Ede, A.E., R.F. Laan, H.J. Blom, R.A. De Abreu & L.B. van de Putte (1998) *Semin. in Arthritis Rheu.* **27**: 277-292.
25. Buttgerit, F., G.R. Burmester & L.S. Simon (2001) *Am. J. Med.* **110** (Suppl 3A): 13S-9S.
26. Cetiner, M., G. Sener, A.O. Sehirli, E. Eksioğlu-Demiralp, F. Ercan, S. Sirvanci, *et al.* (2005) *Toxicol. Appl. Pharm.* **209**: 39-50.
27. Demiryilmaz, I., E. Sener, N. Cetin, D. Altuner, B. Suleyman, F. Albayrak, *et al.* (2012) *Med. Sci. Monit.* **18**: BR475-81.
28. Clarkson, P.M. & H.S. Thompson (2000) *Am. J. Clin. Nutr.* **72**: 637S-46S.
29. Yeum, K.J., R.M. Russell, N I. Krinsky & G. Aldini (2004) *Arch. Biochem. Biophys.* **430**: 97-103.
30. Aguilar, A., R. Alvarez-Vijande, S. Capdevila, J. Alcoberro & A. Alcaraz (2007) *Transplant. Proc.* **39**: 249-52.
31. Naito, Y., T. Yoshikawa, T. Kaneko, S. Iinuma, S. Nishimura, S. Takahashi, *et al.* (1993) *J. Clin. Gastroenterol.* **17** (Suppl 1): S99-103.
32. Milligan, J. R. & J. F. Ward (1994) *Radiat. Res.* **137**: 295-9.
33. Grollman, A.P. & M. Moriya (1993) *Trends Genet.* **9**: 246-9.
34. Borekci, B., O.E. Yapca, M.I. Turan, M.A. Gul & U. Isaoglu (2013) *Lat. Am. J. Pharm.* **32**: 512-7.
35. Dixon, M.F., R.M. Genta, J.H. Yardley & P. Correa (1996) *Am. J. Surg. Pathol.* **20**: 1161-81.
36. Laine, L., F. Cominelli, R. Sloane, V. Casini-Raggi, M. Marin-Sorensen & W.M. Weinstein (1995) *Aliment. Pharmacol. Ther.* **9**: 127-35.
37. Bandyopadhyay, U., K. Biswas, D. Bandyopadhyay, C.K. Ganguly & R.K. Banerjee (1999) *Mol.Cell. Biochem.* **202**: 31-6.
38. Santucci, L., S. Fiorucci, M. Giansanti, P.M. Brunori, F.M. Di Matteo & A. Morelli (1994) *Gut* **35**: 909-15.
39. Kozol, R., A. Kopatsis, S. E. Fligiel, R. Czanko & D. Callewaer (1994) *Digest. Dis. Sci.* **39**: 138-44.
40. Sugimoto, N., N. Yoshida, T. Yoshikawa, Y. Nakamuara, H. Ichikawa, Y. Naito *et al.* (2000) *Digest. Dis. Sci.* **45**: 599-605.
41. Geetha, S., M. Sai Ram, V. Singh, G. Ilavazhagan & R.C. Sawhney (2002) *J. Ethnopharmacol.* **79**: 373-8.
42. Geetha, S., M. Sai Ram, S.S. Mongia, V. Singh, G. Ilavazhagan & R.C. Sawhney (2003) *J. Ethnopharmacol.* **87**: 247-51.